

The Butterfly Bone - the Sphenoid *part one* By Caroline Barrow

Previous articles have looked at the intricacies of a few bones of the skull. I wonder if you have a favourite? While the maxilla and temporals are up there, the sphenoid is also often favoured for its delicacy and butterfly-like beauty. Its greater and lesser wings flare out from a central body and the delicate pterygoid processes point downwards, as anchors for the palatines of the back of the hard palate. See what you think...

One of the key reasons many people working with CranioSacral Therapy love this bone is because it is a linchpin in the cranium: it articulates with all the other cranial bones. In addition to these (the frontal, temporals, parietals, occiput and ethmoid) it meets the vomer, the palatines and the maxilla behind the hard palate, and the zygoma in the lateral part of the orbit. Cranial osteopath Dr Sutherland, first described the variety of 'lesions' it can get into, ie the different directions it can very subtly twist or be twisted into and the effects it can have on its neighbours if this occurs – or of course the effect its neighbours can have on it! As we will see shortly there is so much going on in, around and through this bone that working with it can have quite an effect.

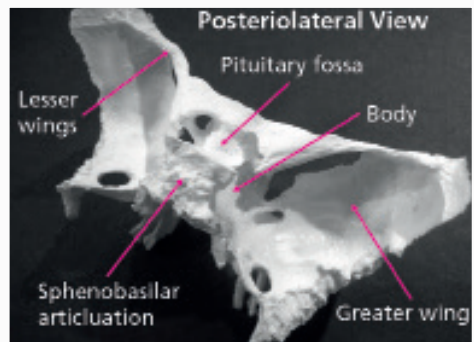
The easiest place to start looking at it is from inside the cranium. You see the curves of the greater wings as they make up part of the middle fossa of the cranial floor and the body in the midline with its rectangular bumpy surface for articulation with the occiput at the sphenobasilar junction. This is a synchondrosis, or a fibrous joint that ossifies by the mid 20s or so; it is also a joint that causes some to question how the sphenoid can have any even slight movement from the osteopathic/craniosacral standpoint, but that is a topic for another day!

Most of the lateral side of the greater wing articulates with the squamous part of the temporal bone, the very top part reaching up to the parietal, while the more posterior edge aligns with the petrous part of the temporals.



Anterior midline (at the front, in the middle!) is the articulation with the delicate ethmoid, which extends inferiorly a cm or two, ('into the page' in the image above) as these bones make up the roof of the nasal cavity.

One delicate feature of this bone is the lesser wing. This is a very thin piece that reaches out sideways from either side of the body, making up the very back part of the anterior cranial fossa (front top shelf in which the brain sits) articulating with the frontal bone as it does so. When you look at many models it appears as if the lesser wing joins the greater at its outer edge, but in fact in life the connection between these two is made by the frontal bone. There is a large hole between the greater and lesser wings which we will look at next time.



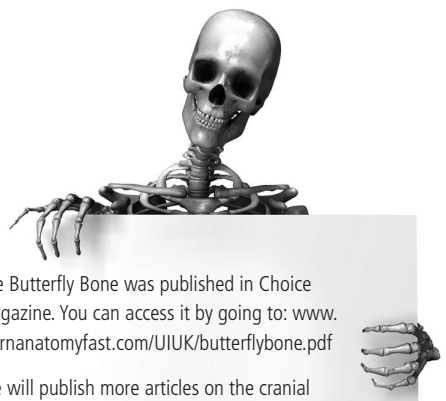
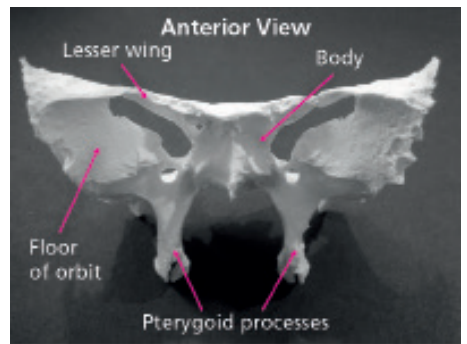
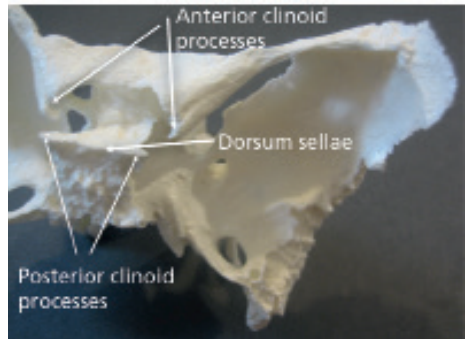
The inward curving ends of the lesser wing attach the tentorium cerebelli, one of the big sheets of the dural membrane which slides in between the underside of the temporal lobe of the cerebrum and on top of the cerebellum, as do two upward pointing pieces at the back section of the body. They are called the anterior and posterior clinoid processes.

The central area is called the body of the sphenoid and is also full of features. Inside the bone itself are two holes, separated by a septum: the sphenoidal sinuses. Lined with mucous membranes like the other sinuses in this area – we saw the maxillary sinus last time and they are also present in the frontal bone and ethmoid – it has a tiny hole from it allowing it to drain into the upper nasal cavity.

In the middle of the body of the sphenoid is a dip or fossa called the sella turcica or pituitary fossa in which the pituitary gland sits. There is a small rectangular chunk of bone that sticks up at the back of this known as the dorsum sellae; this is the piece those posterior clinoid processes come from.

Looking from the underside of the skull you can see the two pterygoid ('ter-a-goid') processes hanging down, each splitting into a medial and lateral pterygoid plate to which attach the medial and lateral pterygoid muscles of..... the TMJ. So here is another strong connection to another bone, the mandible, albeit through muscular attachments. These two pterygoid plates are also important for a connection with the palatines which is a more complex arrangement but just make a note of their position for now and if you really want to know more about that then let me know.

I know I've missed a few but those are the main features of the bone – next time we will take a look at what passes through the number of holes within and between it.



The Butterfly Bone was published in Choice magazine. You can access it by going to: www.learnanatomyfast.com/UIUK/butterflybone.pdf

We will publish more articles on the cranial and facial bones as time goes on and you can also see them in colour on the weblinks: www.learnanatomyfast.com/UIUK/articles.htm

Part 2 [here](#).